

LETTER TO THE EDITOR

Serologic status and safety of inactivated Covid-19 vaccine for hepatocellular carcinoma patients with cirrhosis after curative liver resection

Dear Editor,

Patients with hepatocellular carcinoma (HCC) usually have concomitant chronic liver diseases or cirrhosis, which contribute to a high risk of hepatic decompensation and increased mortality following the coronavirus disease 2019 (Covid-19) infection [1–3]. Worldwide, approximately 54% of HCC cases are associated with hepatitis B virus (HBV) infection [1]. Cirrhotic patients after curative hepatectomy for HBV-related HCC represent a special group of patients. Although cirrhotic patients have low immunogenicity to Covid-19 vaccination and are recommended to be prioritized for it, the safety and immunogenicity have not been observed in cirrhotic patients with a history of hepatectomy for HCC [2–4]. In this study, we explored the immunogenicity and safety after Covid-19 vaccination in patients with liver cirrhosis and a history of hepatectomy for HCC.

We retrospectively conducted a study involving 210 cirrhotic patients following curative hepatectomy for HBV-related HCC and 114 age-matched vaccinated controls (Supplemental Table S1). All participants had negative Covid-19 polymerase chain reaction (PCR)-based analyses before receiving two doses of inactivated Covid-19 vaccine (Sinovac Biotech Co., Ltd.TM). Information regarding the serologic status and safety profile for such a vaccination course was assessed. Whole blood was extracted between day-14 and day-30 post-complete vaccine administration. All participants were analyzed from October 2021 to November 2021, after the follow-up duration from July 2021 to September 2021. The primary study endpoint was the immunogenicity of Covid-19 vaccination.

Abbreviations: HCC, hepatocellular carcinoma; Covid-19, coronavirus disease 2019; HBV, hepatitis B virus; PCR, polymerase chain reaction; SARS-CoV-2, severe acute respiratory syndrome coronavirus 2; TBIL, total bilirubin; ALT, alanine aminotransferase; AST, aspartate aminotransferase; AFP, alpha-fetoprotein; PIVKA-II, protein driven through vitamin K absence or antagonist-II; OR, odds ratio; CI, confidence interval.

The secondary study endpoint was the safety of the Covid-19 vaccine, including local and systemic adverse events after Covid-19 vaccination, liver dysfunction and tumor recurrence.

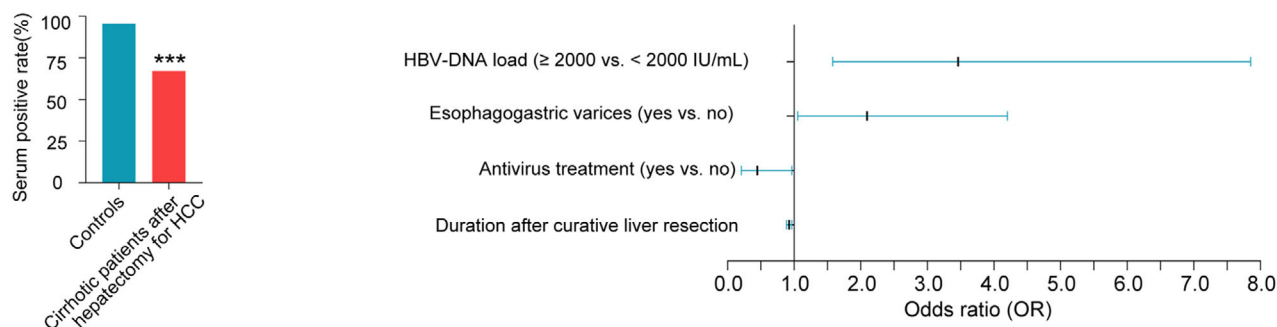
The levels for inhibiting antibodies in serum against severe acute respiratory syndrome coronavirus 2 (SARS-CoV-2) spike antigen were evaluated across all study participants using enzyme-linked immunosorbent assay (ELISA) (Beijing Wantai Biological Pharmacy Enterprise, China) [5]. We found that the immunogenicity for inactivated Covid-19 vaccine was significantly reduced, with positive anti-spike serology in 67.1% of cirrhotic patients after curative liver resection for HCC, in comparison to control-cohort that had 95.6% ($P < 0.001$) (Figure 1A and Supplementary Table S1 and S2). Based on our multivariate analysis, independent factors associated significantly with seronegative reactions to the Covid-19 vaccine were high HBV-DNA loads (odds ratio [OR]: 3.46, 95% confidence interval [CI]: 1.58–7.85, $P = 0.002$) and esophagogastric varices (OR: 2.10, 95% CI: 1.05–4.20, $P = 0.036$) (Supplementary Table S3). Antiviral therapy (tenofovir or entecavir) (OR: 0.45, 95% CI: 0.21–0.97, $P = 0.040$) together with duration after curative liver resection for HCC (OR: 0.92, 95% CI: 0.88–0.97, $P = 0.001$) were inversely related to seronegative responses (Figure 1A and Supplementary Table S3).

Our further analysis revealed no significant differences in hepatic function before and after Covid-19 vaccination among cirrhotic patients (Figure 1B). Although one study showed that Covid-19 vaccination seemed to have an adequate safety profile and decent serological outcomes within oncology clinical cases, satisfactory oncological outcomes following Covid-19 vaccination were not observed as yet [6]. In this present study, the serum tumor markers of cirrhotic HCC patients treated with radical resection, including alpha-fetoprotein (AFP) and prothrombin induced by vitamin K absence-II (PIVKA-II), detected before and after Covid-19 vaccination displayed no sta-

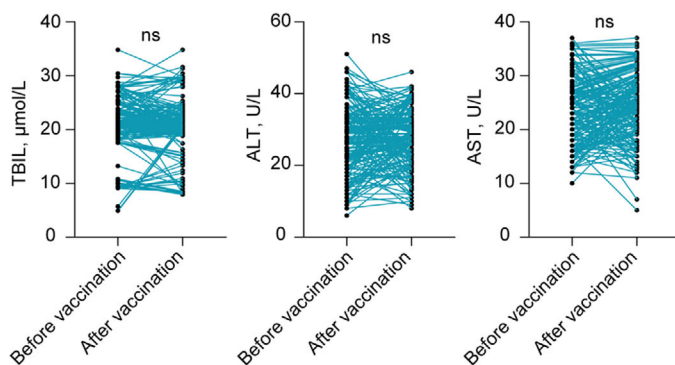
This is an open access article under the terms of the [Creative Commons Attribution-NonCommercial-NoDerivs](https://creativecommons.org/licenses/by-nc-nd/4.0/) License, which permits use and distribution in any medium, provided the original work is properly cited, the use is non-commercial and no modifications or adaptations are made.

© 2022 The Authors. *Cancer Communications* published by John Wiley & Sons Australia, Ltd. on behalf of Sun Yat-sen University Cancer Center.

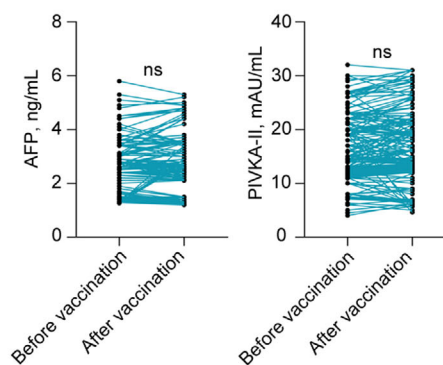
(A) The independent factors for seronegative in anti-SARS-CoV-2 spike antibodies



(B) Liver function of patients with cirrhosis



(C) Tumor markers of patients with cirrhosis



(D) Local and systemic adverse events within 7 Days

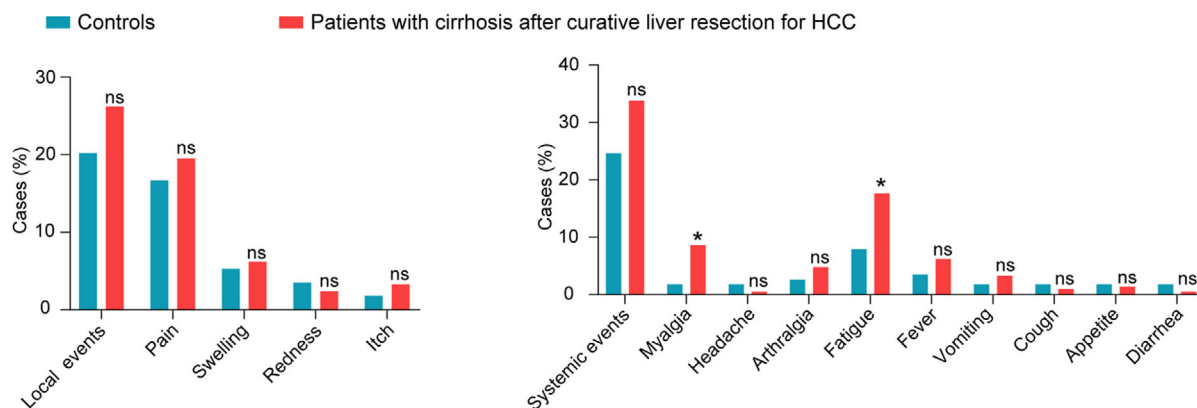


FIGURE 1 Serologic status and safety of inactivated Covid-19 vaccine in patients with cirrhosis after curative liver resection for HCC.

(A) The seropositive rates in controls and cirrhotic patients with HCC, respectively (left panel), and four independent factors for seronegative response to inactivated Covid-19 vaccine in cirrhotic patients with HCC (right panel). (B) Liver function assessment in patients with cirrhosis before and after Covid-19 vaccination. (C) Tumor serum markers assessment in patients with cirrhosis before and after Covid-19 vaccination. (D) Local and systemic adverse effects (mild-to-moderate) in all the participants post-two doses of inactivated Covid-19 vaccine.

* represents $P < 0.05$ and *** represents $P < 0.001$.

Abbreviations: Covid-19, coronavirus disease 2019; HCC, hepatocellular carcinoma; TBIL, total bilirubin; ALT, alanine aminotransferase; AST, aspartate aminotransferase; AFP, alpha-fetoprotein; PIVKA-II, protein driven through vitamin K absence or antagonist-II; ns, not significant.

tistical significance (Figure 1C). In addition, 2-3 months after Covid-19 vaccination, cirrhotic patients experienced no events of suspected or confirmed liver dysfunction and tumor recurrence.

Our study further indicated no severe adverse effects within seven days after Covid-19 vaccination in any participants. The frequencies of local mild to moderate adverse events were similar across cohorts. Although patients with cirrhosis had higher rates of myalgia and fatigue following Covid-19 vaccination compared to controls, total systemic mild-to-moderate adverse events were comparable in both groups (Figure 1D and Supplementary Table S4).

In our study, the patients with cirrhosis were all related to chronic HBV infection. Antiviral therapy can reduce liver inflammation and fibrosis progression in patients with HBV-related HCC after hepatectomy [7]. High HBV-DNA load is an independent risk factor for seropositivity of anti-SARS-CoV2 spike antibodies, and antiviral therapy was found to be a protective factor for seropositivity after Covid-19 vaccination. In addition, patients with liver cirrhosis and esophagogastric varices have a high risk of decompensated cirrhosis [8], and our results indicated these patients have low immunogenicity after Covid-19 vaccination. In our study, the patients with liver cirrhosis had a low incidence of adverse reactions and abnormal liver function after the Covid-19 vaccination, and no tumor recurrence was observed, indicating that Covid-19 vaccination could be strengthened in such patients.

There were some limitations in this study. First, the serum antibodies against spike antigen were detected based on ELISA rather than plaque reduction neutralization test (PRNT), which is considered the gold standard for anti-SARS-CoV2 spike antibody detection. Second, this study only showed the levels of total anti-SARS-CoV2 spike antibodies in serum rather than the specific levels of IgG, IgA and IgM. Third, there might be inherent flaws due to the retrospective nature of this study; thus, randomized trials are required to confirm the results.

In conclusion, this study revealed that inactivated Covid-19 vaccines could be safe, and a low immunologic response to Covid-19 vaccines was developed in cirrhotic patients after curative liver resection for HCC. Factors influencing seronegative responses included HBV-DNA loads, esophagogastric varices, antiviral treatment and duration after curative liver resection. Thus, HBV-related HCC patients after hepatectomy undergoing antivirals should not withhold pharmacotherapies during the vaccine-administration timeframe.

AUTHOR CONTRIBUTIONS

Fuchen Liu and Xiaochen Feng contributed equally to this work. Conceptualization: Hui Liu. Acquisition, analysis,

or interpretation of data: Fuchen Liu, Xiaochen Feng, Jin Du and Minghao Ruan. Drafting and writing: Fuchen Liu, Xiaochen Feng and Hui Liu. Hui Liu is responsible for the accuracy of all data and aspects of this work.

ACKNOWLEDGMENTS

Not applicable

CONFLICT OF INTEREST

The authors declare no conflicts of interest.

DATA AVAILABILITY STATEMENT


The datasets associated with this present study could be made available from the corresponding author upon reasonable request.

ETHICS APPROVAL AND CONSENT TO PARTICIPATE

This study was approved by the Ethics Committee of Eastern Hepatobiliary Surgery Hospital (EHBHXY2022-K-003), and all participants were provided with written informed consent.

CONSENT FOR PUBLICATION

Not applicable.

Fuchen Liu
Xiaochen Feng
Jin Du
Minghao Ruan
Hui Liu 

The Third Department of Hepatic Surgery, Eastern Hepatobiliary Surgery Hospital, Third Affiliated Hospital, Second Military Medical University, Naval Medical University, Shanghai, P. R. China

Correspondence

Hui Liu, The Third Department of Hepatic Surgery, Eastern Hepatobiliary Surgery Hospital, Third Affiliated Hospital, Second Military Medical University, Naval Medical University, No. 225, Changhai Road, Shanghai, P. R. China

Email: liuhuigg@hotmail.com

ORCID

Hui Liu  <https://orcid.org/0000-0003-4599-5702>

REFERENCES

1. Cornberg M, Buti M, Eberhardt CS, Grossi PA, Shouval D. EASL position paper on the use of COVID-19 vaccines in patients with chronic liver diseases, hepatobiliary cancer and liver transplant recipients. *J Hepatol.* 2021;74(4):944-51.

2. Fix OK, Blumberg EA, Chang KM, Chu J, Chung RT, Goacher EK, et al. American Association for the Study of Liver Diseases Expert Panel Consensus Statement: Vaccines to Prevent Coronavirus Disease 2019 Infection in Patients With Liver Disease. *Hepatology*. 2021;74(2):1049-64.
3. Marjot T, Webb GJ, Barritt ASt, Moon AM, Stamataki Z, Wong VW, et al. COVID-19 and liver disease: mechanistic and clinical perspectives. *Nat Rev Gastroenterol Hepatol*. 2021;18(5):348-64.
4. Ai J, Wang J, Liu D, Xiang H, Guo Y, Lv J, et al. Safety and Immunogenicity of SARS-CoV-2 Vaccines in Patients With Chronic Liver Diseases (CHESS-NMCID 2101): A Multicenter Study. *Clin Gastroenterol Hepatol*. 2022;20(7):1516-24.e2.
5. Kamar N, Abravanel F, Marion O, Couat C, Izopet J, Del Bello A. Three Doses of an mRNA Covid-19 Vaccine in Solid-Organ Transplant Recipients. *N Engl J Med*. 2021;385(7):661-2.
6. Goshen-Lago T, Waldhorn I, Holland R, Szwarcwort-Cohen M, Reiner-Benaim A, Shachor-Meyouhas Y, et al. Serologic Status and Toxic Effects of the SARS-CoV-2 BNT162b2 Vaccine in Patients Undergoing Treatment for Cancer. *JAMA Oncol*. 2021;7(10):1507-13.
7. Jiang E, Shangguan AJ, Chen S, Tang L, Zhao S, Yu Z. The progress and prospects of routine prophylactic antiviral treatment in hepatitis B-related hepatocellular carcinoma. *Cancer Lett*. 2016;379(2):262-7.
8. Berzigotti A, Reig M, Abraldes JG, Bosch J, Bruix J. Portal hypertension and the outcome of surgery for hepatocellular carcinoma in compensated cirrhosis: a systematic review and meta-analysis. *Hepatology*. 2015;61(2):526-36.

SUPPORTING INFORMATION

Additional supporting information can be found online in the Supporting Information section at the end of this article.