

LETTER TO THE EDITOR

Clinical outcomes of second-line treatment following first-line VEGFR-TKI failure in patients with metastatic renal cell carcinoma: a comparison of axitinib alone and axitinib plus anti-PD-1 antibody

Dear editor,

The prognosis of metastatic renal cell carcinoma (mRCC) has been significantly improved with the development and widespread use of vascular endothelial growth factor (VEGF) pathway inhibitors and mammalian target of rapamycin (mTOR) pathway inhibitors [1]. For the past decade, the standard of care utilized in the first-line setting was VEGF-targeted therapies. Recently, the mRCC treatment landscape has rapidly changed with the exploration of combinations of immune checkpoint inhibitors (ICIs) and anti-VEGF agents [2,3]. The Keynote-426 trial demonstrated both progression-free survival (PFS) and overall survival (OS) advantages of axitinib plus pembrolizumab over sunitinib for untreated advanced RCC patients [2]. Based on these results, axitinib plus pembrolizumab, cabozantinib plus nivolumab, lenvatinib plus pembrolizumab, and nivolumab plus ipilimumab have been recommended as first-line treatment in recent guidelines [3]. However, axitinib plus pembrolizumab as first-line treatment for mRCC is only approved in limited countries, in which China is not included. Vascular endothelial growth factor receptor-tyrosine kinase inhibitors (VEGFR-TKIs) remain a recommended option as first-line therapy in China and in other countries. Nivolumab, cabozantinib, or axitinib remains the standard care for patients who failed first-line therapy with VEGFR-TKI. Considering that axitinib plus anti-programmed cell death protein 1 (PD-1) antibody was expected to have a better oncological outcome than axitinib alone owing to first-line study

results [2], the subsequent therapy algorithm after first-line VEGFR-TKI failure needs to be redefined. So far, there is no research published on VEGFR-TKI and ICI combination therapy after first-line VEGFR-TKI failure. In this context, the present retrospective multi-center study was aimed to compare the objective response rate (ORR), PFS, OS, and toxicities between axitinib plus anti-PD-1 antibody and axitinib alone for mRCC after first-line VEGFR-TKI failure.

Clinical data were retrieved from the electronic medical records of mRCC patients treated at 5 participating centers between October 2015 and October 2020. The patient selection and assessments are detailed in the Supplementary file of **Patients and Methods**. A total of 255 patients were included in this study, of whom 116 received axitinib plus anti-PD-1 antibody combination therapy, and 139 received axitinib alone (Supplementary Figure S1). Anti-PD-1 antibody agents used in this study were used off label, including pembrolizumab ($n = 32$, 27.6%), nivolumab ($n = 6$, 5.2%), toripalimab ($n = 42$, 36.2%), sintilimab ($n = 32$, 27.6%), and tislelizumab ($n = 4$, 3.4%). All patients were aware of this situation and signed informed consent before treatment. Supplementary Table S1 shows the baseline characteristics of these 255 patients.

The best responses of patients are shown in Supplementary Table S2. According to Response Evaluation Criteria in Solid Tumors version 1.1, only 2 patients in the combination group had complete response (CR), while none in the axitinib group had CR. Meanwhile, 37 patients in the combination group and 28 in the axitinib group were determined to have partial response (PR). The ORR in the combination group was significantly higher than that in the axitinib group (33.6% vs. 20.1%, $P = 0.015$).

After a median follow-up period of 25.7 (95% confidence interval [CI] = 15.4–36.0) months from the start of second-line treatment, the median PFS was 11.7 (95% CI = 9.2–14.2)

Abbreviations: VEGFR-TKI, vascular endothelial growth factor receptor-tyrosine kinase inhibitor; ICI, immune checkpoint inhibitor; PD-1, programmed cell death protein 1; mRCC, metastatic renal cell carcinoma; PFS, progression-free survival; OS, overall survival; ORR, objective response rate; IMDC, International Metastatic Renal Cell Carcinoma Database Consortium; AEs, adverse events

This is an open access article under the terms of the [Creative Commons Attribution-NonCommercial-NoDerivs](https://creativecommons.org/licenses/by-nc-nd/4.0/) License, which permits use and distribution in any medium, provided the original work is properly cited, the use is non-commercial and no modifications or adaptations are made.

© 2021 The Authors. *Cancer Communications* published by John Wiley & Sons Australia, Ltd. on behalf of Sun Yat-sen University Cancer Center

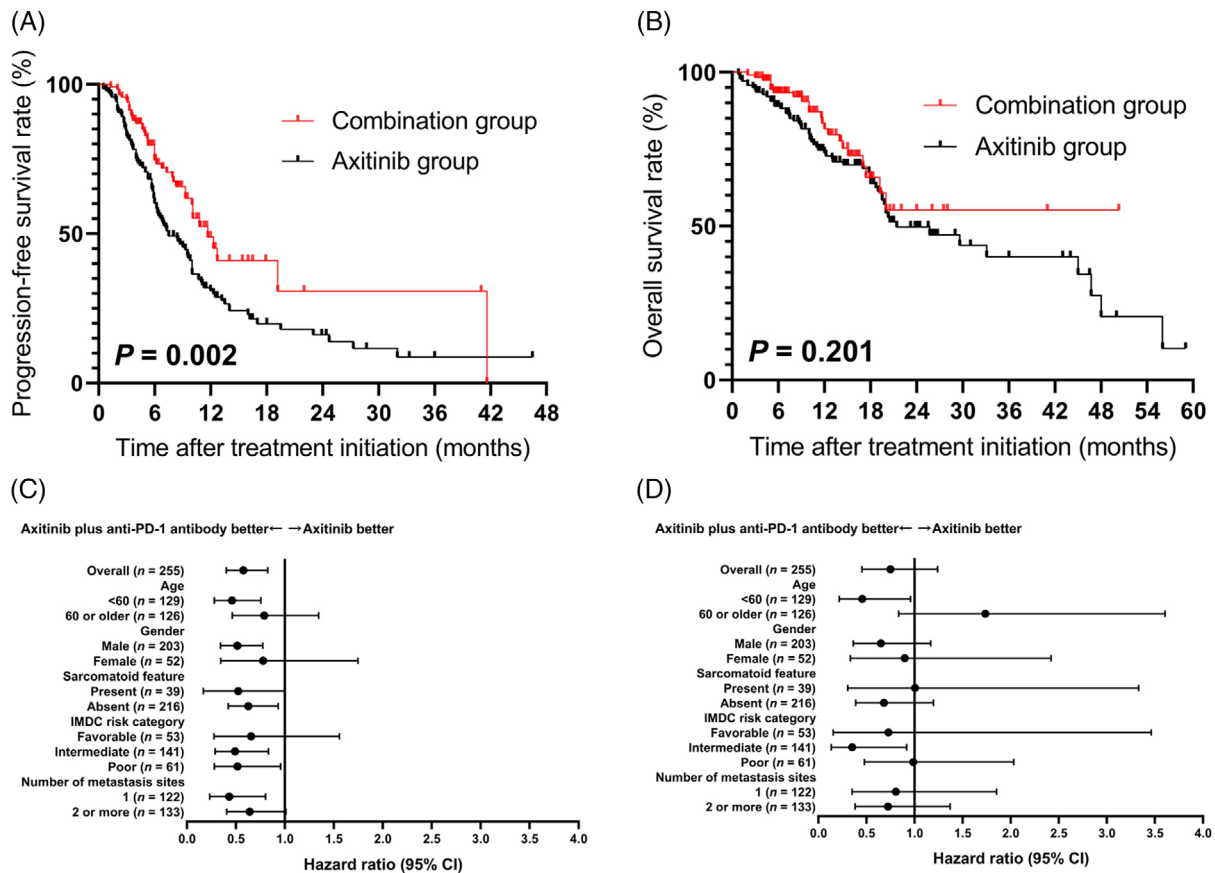


FIGURE 1 PFS, OS, and subgroup analysis of 255 mRCC patients who received axitinib alone or axitinib plus anti-PD-1 antibody following first-line VEGFR-TKI failure. A. Kaplan-Meier PFS curves of patients treated with combination therapy and axitinib alone. B. Kaplan-Meier OS curves of patients treated with combination therapy and axitinib alone. C. Subgroup analysis of PFS. D. Subgroup analysis of OS

Abbreviations: PFS, progression-free survival; OS, overall survival; mRCC, metastatic renal cell carcinoma; PD-1, programmed cell death protein 1; VEGFR-TKI, vascular endothelial growth factor receptor-tyrosine kinase inhibitor; IMDC, International Metastatic Renal Cell Carcinoma Database Consortium.

months for patients treated with combination therapy and 7.5 (95% CI = 5.2-9.8) months for patients treated with axitinib alone. The PFS of the combination group was significantly longer than that of the axitinib group ($P = 0.002$) (Figure 1A). The median OS was not reached in the combination group and was 21.4 (95% CI = 13.7-29.1) months for patients treated with axitinib alone (Figure 1B). No significant difference in OS was found ($P = 0.201$).

Figure 1C shows the subgroup analysis of PFS with respect to baseline characteristics and International Metastatic Renal Cell Carcinoma Database Consortium (IMDC) classification using Cox proportional hazards model. Factors favoring combination therapy included IMDC intermediate risk (hazard ratio [HR] = 0.490, 95% CI = 0.288-0.833) and poor risk (HR = 0.516, 95% CI = 0.279-0.956). However, in the subgroup analysis of OS (Figure 1D), the advantage of combination therapy was only observed in IMDC intermediate-risk mRCC (HR =

0.346, 95% CI = 0.133-0.905). Furthermore, the combination therapy significantly prolonged PFS in patients with (HR = 0.407, 95% CI = 0.167-0.995) or without sarcomatoid features (HR = 0.626, 95% CI = 0.421-0.931).

Next, we evaluated the associations between clinical characteristics and survival. IMDC risk, discontinuation of first-line therapy due to AEs, and second-line regimen were significantly associated with PFS (Supplementary Table S3); IMDC risk was identified as an independent predictor of OS (Supplementary Table S4).

At the time of data analysis, in the combination therapy group, adverse events (AEs) led to discontinuation of either drug in 11 (9.5%) patients, discontinuation of both drugs in 6 (5.2%) patients, and dose reduction of axitinib in 9 (7.8%) patients. While in the axitinib group, 17 (12.2%) patients required dose reduction, and 10 (7.2%) needed drug discontinuation. Major treatment-related adverse events are presented in Supplementary Table S5.

In the present study, axitinib plus anti-PD-1 antibody showed ORR and PFS benefits over axitinib alone in mRCC patients. One concern is whether the benefits of the combination therapy could be observed across all IMDC risk categories. We found that the combination therapy prolonged PFS in the IMDC intermediate- or poor-risk subgroup, but not in the favorable-risk subgroup. However, the OS benefit was only observed in the IMDC intermediate-risk subgroup, probably due to the small number of patients at IMDC poor risk and short follow-up period. According to the subgroup analysis of the Keynote-426 study [4], pembrolizumab plus axitinib prolonged both OS (HR = 0.52, 95% CI = 0.37-0.74) and PFS (HR = 0.67, 95% CI = 0.53-0.85) in patients with IMDC intermediate or poor risk, which were similar to our findings. Based on these results, we speculate that patients with IMDC favorable risk mRCC might have no added benefit from the combination therapy after first-line TKI failure given the high cost of ICI-based therapy and immune-related AEs [5,6], while patients with IMDC intermediate- or poor-risk mRCC might benefit most from the combination therapy.

In patients with mRCC treated with TKIs, sarcomatoid features had been reported to be associated with poor prognosis [7], but recent studies suggested that ICI-based combination therapy could dramatically improve the outcomes of these patients [4,8]. The subgroup analysis of the Keynote-426 study [4] showed a benefit in PFS (HR = 0.54, 95% CI = 0.29-1.00) with combination therapy compared to sunitinib alone in patients with sarcomatoid features, which was similar to our results.

Some side effects of combination therapy seemed to add up numerically [2,9,10]. The rate of grade ≥ 3 liver enzyme elevation was significantly higher in the combination group than in the axitinib group, which was consistent with historic comparisons such as the Keynote-426 study [2].

The limitation of this study was represented by the relatively short follow-up, the retrospective design, and selection bias. The OS data were not mature in the combination group. In addition, patients who received cabozantinib, ICI alone, or ICI combination as second-line therapy were not included in this study because cabozantinib and anti-CTLA-4 antibodies were not commercially available in China during the study period. Nevertheless, the ideal order of sequential therapy remains unclear, and the combinational use of axitinib plus anti-PD-1 antibody in this setting should be validated in future prospective studies as a standard of care.

In conclusion, among mRCC patients with first-line VEGFR-TKI failure, second-line treatment with axitinib plus anti-PD-1 antibody may prolong PFS and increase ORR as compared with axitinib alone.

ACKNOWLEDGEMENTS

Not applicable.

AUTHORS' CONTRIBUTIONS

J.H., S.W., J.G., Q.W. and W.X. designed the research. W.X., S.W., J.G., Q.W. and W.C. provided executive support and data surveillance and performed the patient selection process. Y.W., H.Z., X.H., P.W., W.C. and Y.Y. acquired and analyzed the data. J.H., Y.W., H.Z., X.H., P.W., W.C. and Y.Y. wrote the manuscript. H.Z., J.Z., W.K., J.Z. and Y.H. revised the manuscript. All authors reviewed the manuscript critically and approved the content.

COMPETING INTERESTS

The authors declare that no competing interests exist.

AVAILABILITY OF DATA AND MATERIALS

Not applicable.

CONSENT FOR PUBLICATION

Not applicable.

ETHICS APPROVAL AND CONSENT TO PARTICIPATE

This study was conducted in accordance with the ethical standards of the Declaration of Helsinki and approved by the independent ethics committee of all 5 participating centers.

FUNDING

This study was supported by Shanghai Science and Technology Commission Research Project (21ZR1438900) and the Incubating Program for Clinical Research and Innovation of Renji Hospital (PYXJS16-008, PYIII20-07).

CONFLICT OF INTEREST DISCLOSURES

The authors have declared no conflicts of interest.

Jiwei Huang^{1,†} 
 Yueming Wang^{1,†}
 Haoran Zhang^{2,†}
 Xiaoyi Hu^{3,†}
 Ping Wang^{4,†}
 Wen Cai^{5,†}
 Yichu Yuan^{5,†}
 Hao Zeng²
 Jin Zhang¹
 Wen Kong¹
 Yiran Huang¹
 Shuo Wang⁴
 Jianming Guo³

Qiang Wei²
Wei Xue¹

¹ Department of Urology, Renji Hospital, School of Medicine, Shanghai Jiao Tong University, Shanghai 200127, P. R. China

² Department of Urology, West China Hospital, Sichuan University, Chengdu, Sichuan 610041, P. R. China

³ Department of Urology, Zhongshan Hospital, Fudan University, Shanghai 200032, P. R. China

⁴ Department of Urology, First Affiliated Hospital, Zhejiang University School of Medicine, Hangzhou, Zhejiang 310003, P. R. China

⁵ Department of Urology, Second Affiliated Hospital, Zhejiang University School of Medicine, Hangzhou, Zhejiang 310009, P. R. China

Correspondence

Jiwei Huang, Department of Urology, Ren Ji Hospital, School of Medicine, Shanghai Jiao Tong University, 1630 Dongfang Road, Pudong District, Shanghai 200127, P. R. China

Email: huangjiwei@renji.com

Shuo Wang, Department of Urology, First Affiliated Hospital, Zhejiang University School of Medicine, Hangzhou, Zhejiang 310003, P. R. China

Email: shuowang11@zju.edu.cn

Jianming Guo, Department of Urology, Zhongshan Hospital, Fudan University, 180 Fenglin Road, Xuhui District, Shanghai 200032, P. R. China

Email: guo.jianming@zs-hospital.sh.cn

Qiang Wei, Department of Urology, West China Hospital, Sichuan University, Chengdu, Sichuan 610041, China

Email: weiqiang933@126.com

Wei Xue, Department of Urology, Ren Ji Hospital, School of Medicine, Shanghai Jiao Tong University, 1630 Dongfang Road, Pudong District, Shanghai 200127, China

Email: uoroxuewei@163.com

†These authors have contributed equally to this work.

ORCID

Jiwei Huang  <https://orcid.org/0000-0002-1463-670X>

REFERENCES

1. Choueiri TK, Motzer RJ. Systemic Therapy for Metastatic Renal-Cell Carcinoma. *N Engl J Med.* 2017;376(4):354-366. <https://doi.org/10.1056/NEJMra1601333>

2. Rini BI, Plimack ER, Stus V, Gafanov R, Hawkins R, Nosov D, et al. Pembrolizumab plus Axitinib versus Sunitinib for Advanced Renal-Cell Carcinoma. *N Engl J Med.* 2019;380(12):1116-1127. <https://doi.org/10.1056/NEJMoa1816714>
3. Bedke J, Albiges L, Capitanio U, Giles RH, Hora M, Lam TB, et al. The 2021 Updated European Association of Urology Guidelines on Renal Cell Carcinoma: Immune Checkpoint Inhibitor-based Combination Therapies for Treatment-naïve Metastatic Clear-cell Renal Cell Carcinoma Are Standard of Care [published online ahead of print, 2021 May 29]. *Eur Urol.* 2021;S0302-2838(21)00322-5. <https://doi.org/10.1016/j.eururo.2021.04.042>
4. Brian R, Elizabeth P, Viktor S, Rustem G, Robert H, Dmitry N, et al. Pembrolizumab (pembro) plus axitinib (axi) versus sunitinib as first-line therapy for metastatic renal cell carcinoma (mRCC): Outcomes in the combined IMDC intermediate/poor risk and sarcomatoid subgroups of the phase 3 KEYNOTE-426 study. *J Clin Oncol.* 2019;37(15s):4500-4500. https://doi.org/10.1200/JCO.2019.37.15_suppl.4500
5. Sarfaty M, Leshno M, Gordon N, Moore A, Neiman V, Rosenbaum E, et al. Cost Effectiveness of Nivolumab in Advanced Renal Cell Carcinoma. *Eur Urol.* 2018;73(4):628-634. <https://doi.org/10.1016/j.eururo.2017.07.041>
6. Baxi S, Yang A, Gennarelli RL, Khan N, Wang Z, Boyce L, et al. Immune-related adverse events for anti-PD-1 and anti-PD-L1 drugs: systematic review and meta-analysis. *BMJ.* 2018;360:k793. Published 2018 Mar 14. <https://doi.org/10.1136/bmj.k793>
7. Korenbaum C, Pierard L, Thiéry A, Story F, Lindner V, Lang H, et al. Treatments, Outcomes, and Validity of Prognostic Scores in Patients With Sarcomatoid Renal Cell Carcinoma: A 20-Year Single-Institution Experience. *Clin Genitourin Cancer.* 2018;16(3):e577-e586. <https://doi.org/10.1016/j.clgc.2017.12.005>
8. Tannir NM, Signoretti S, Choueiri TK, McDermott DF, Motzer RJ, Flaifel A, et al. Efficacy and Safety of Nivolumab Plus Ipilimumab versus Sunitinib in First-line Treatment of Patients with Advanced Sarcomatoid Renal Cell Carcinoma. *Clin Cancer Res.* 2021;27(1):78-86. <https://doi.org/10.1158/1078-0432.CCR-20-2063>
9. Grimm MO, Leucht K, Grünwald V, Foller S. New First Line Treatment Options of Clear Cell Renal Cell Cancer Patients with PD-1 or PD-L1 Immune-Checkpoint Inhibitor-Based Combination Therapies. *J Clin Med.* 2020;9(2):565. Published 2020 Feb 19. <https://doi.org/10.3390/jcm9020565>
10. Motzer RJ, Penkov K, Haanen J, Rini B, Albiges L, Campbell MT, et al. Avelumab plus Axitinib versus Sunitinib for Advanced Renal-Cell Carcinoma. *N Engl J Med.* 2019;380(12):1103-1115. <https://doi.org/10.1056/NEJMoa1816047>

SUPPORTING INFORMATION

Additional supporting information may be found online in the Supporting Information section at the end of the article.